Expert Review of Medical Devices

ISSN: 1743-4440 (Print) 1745-2422 (Online) Journal homepage: http://www.tandfonline.com/loi/ierd20

Evaluation of Pipeline Flex delivery system for the treatment of unruptured aneurysms

Pedro Aguilar-Salinas, Leonardo B.C. Brasiliense, Douglas Gonsales, Bartley Mitchell, Andrey Lima, Eric Sauvageau & Ricardo Hanel

To cite this article: Pedro Aguilar-Salinas, Leonardo B.C. Brasiliense, Douglas Gonsales, Bartley Mitchell, Andrey Lima, Eric Sauvageau & Ricardo Hanel (2016): Evaluation of Pipeline Flex delivery system for the treatment of unruptured aneurysms, Expert Review of Medical Devices, DOI: 10.1080/17434440.2016.1231573

To link to this article: http://dx.doi.org/10.1080/17434440.2016.1231573

Published online: 20 Sep 2016.

EXPERT REVIEW OF MEDICAL DEVICES, 2016
http://dx.doi.org/10.1080/17434440.2016.1231573

Taylor & Francis
Taylor & Francis Group

DEVICE PROFILE

Evaluation of Pipeline Flex delivery system for the treatment of unruptured aneurysms

Pedro Aguilar-Salinas [a], Leonardo B.C. Brasiliense [b], Douglas Gonsales [a], Bartley Mitchell[a], Andrey Lima[a], Eric Sauvageau [a] and Ricardo Hanel[a]

[a]Lyerly Neurosurgery, Baptist Health, Jacksonville, FL, USA; [b]Division of Neurosurgery, University of Arizona, Tucson, AZ, USA

ABSTRACT

Introduction: Refinements in endovascular technology have revolutionized the treatment of intracranial aneurysms (IAs) with the development of flow-diversion technology. The first generation of the Pipelin Embolization Device (PED) has demonstrated its safety and efficacy. However, the deployment technique was a difficult task that often led to complex maneuvers. The Pipeline Flex Embolization Device (PED Flex) is the second generation and its introduction has arrived with high expectations due to a completely redesigned delivery system that intends to overcome deployment difficulties seen in the previous generation.

Areas covered: Preclinical studies, mechanism of action of flow-diverters, technical aspects and deployment system of the PED Flex, and clinical outcomes with both PED generations.

Expert commentary: Flow diversion has allowed us to treat lesions that would be otherwise challenging for surgical clipping or unsuitable for other endosaccular strategies. Although the experience with PED Flex is limited, initial results suggest its safety and short-term efficacy.

ARTICLE HISTORY
Received 27 May 2016
Accepted 30 August 2016
Published online 19 September 2016

KEYWORDS
Intracranial aneurysms; unruptured aneurysms; endovascular treatment; flow diversion; pipeline flex embolization device

1. Introduction

An intracranial aneurysm (IA) is a pathologic dilatation of blood vessels, which is generally thought to be multifactorial in nature and poses a high threat to patients based on its risk of rupture [1]. The estimated prevalence of IAs in the general population ranges from 5% to 10% based on imaging and autopsy studies, with a female predominance, and an annual rupture rate of approximately 10 per 100,000. These acquired lesions are usually found at arterial branching sites, and the most frequent location is the anterior cerebral circulation in 85–90% of the cases [2,3]. The most frequent clinical presentation of IAs is acute subarachnoid hemorrhage with approximately 30,000 cases per year in the USA and a mortality rate as high as 66.7% if untreated [4,5]. Initially, the treatment of IAs was performed only in instances of aneurysm rupture, but with the development of microsurgical techniques, neuroimaging, and neuroendovascular technology, the goals of treatment have shifted to include preventive treatment of unruptured lesions to decrease the risk of rupture. Since the first aneurysm clipping in 1937 by Dandy [6] until the early 1990s, traditional microsurgery was the central component of treatment. However, Guglielmi made a radical change in the treatment of IAs with the introduction of detachable coils, thus providing an endosaccular alternative to surgical clipping [7,8]. During the past two decades, the neuroendovascular technology has evolved tremendously, moving towards less invasive techniques, and becoming the treatment of choice for most ruptured and unruptured IAs. Its efficacy and safety have been demonstrated in recent clinical trials [9,10]. Still, complex aneurysms such as large, giant, wide-necked, and fusiform are considered challenging lesions for both classic microsurgical and endovascular techniques. Studies in this subset of lesions have shown a low rate of aneurysm occlusion and a high rate of recanalization with simple-coil embolization, stent-assisted coiling, or balloon-assisted coiling [11–15]. Limitations of coil occlusion, particularly aneurysm recanalization, became apparent in large and wide-necked aneurysms [16]. In order to address this issue, adjunctive techniques such as balloon-assisted coiling, stent-assisted coiling, and complex stent reconstructions were developed to prevent coil prolapse and improve packing density. Balloon-assisted coil embolization showed an improvement in occlusion rates, but it is limited by the risk of coil prolapse into the vessel lumen after balloon deflation [17]. The development of self-expanding intracranial stents allowed mechanical support to coils, which improved coil packing density, and mid- and long-term results have shown excellent rates of occlusion in certain aneurysms ranging from 19% to 98% at latest imaging follow-up but can be associated with a high recanalization rate, estimated at 17.5% in previous studies [18–22]. Double stenting has been reported in aneurysms not amenable to coil embolization, particularly wide-necked aneurysms located in bifurcations that require complex stent reconstructions such as Y or X configurations, which have been shown to be effective to prevent coil protrusion. However, these reconstructions remain technically challenging and associated with a higher procedural rate of complications, which has been reported to be up to 32% of cases [23–25]. Limitations with endosaccular

CONTACT Ricardo Hanel rhanel@lyerlyneuro.com Lyerly Neurosurgery, Baptist Health 800 Prudential Drive, Tower B, 11th Floor, Jacksonville, FL, USA

therapies for complex aneurysms drove the impetus to develop a novel approach for aneurysm occlusion, culminating in the advent of flow-diversion technology. Basically, the concept behind flow diversion relies on reconstruction of the underlying parent vessel instead of filling the aneurysm with embolic agents. Diverting the blood flow away from the aneurysm has been shown to lead to aneurysm occlusion in a delayed fashion rather than immediately after the procedure.

2. Preclinical studies and flow-diversion technology

The observation that intracranial stents were able to modify flow dynamics inside the aneurysm gave rise to the hypothesis that disrupting the inflow to the aneurysm would lead to thrombus formation and subsequently aneurysm occlusion without endosaccular manipulation [26–28]. *In vitro* and *in vivo* animal experimentation confirmed the theoretical concept that reduction of inflow, velocity, and turbulence contributed to progressive thrombosis of sidewall aneurysms [29,30]. Unlike other self-expanding intracranial stents, experimental models suggested that low porosity (open metal-free area) and high pore density (number of pores per area, pores/mm^2) were the most effective features of flow diverters in order to decrease blood flow into the aneurysm, with an optimal range between 60% and 76% [31–33]. However, a better understanding of flow diverters has shown that their mechanism of action is beyond an interruption between parent artery and aneurysm interface. It is a complex process that involves mechanical, anatomical, physiological, and biological mechanisms that eventually restore the anatomy and physiology of the vessel. First, the reconstruction between normal arterial segments leads to an immediate flow disruption to the aneurysm with redirection to the parent vessel, thus reducing the velocity and shear stress on the lesion wall. Second, endosaccular blood stasis favors aneurysm thrombosis and progression towards complete occlusion and obliteration over time. Finally, progressive endothelialization over the metallic mesh becomes a biological seal across the diseased segment of the parent artery. Regarding endothelialization, initial *in vivo* preclinical studies in rabbits showed that side branches and vessel perforators are spared despite endothelialization of the device because of sufficient pressure gradient to maintain blood flow through the stent pores [34–36]. However, a recent study suggested that the pattern of neointimal formation is related to the wall shear stress (WSS), which means that endothelial proliferation is promoted in the setting of low WSS both in the reconstructed parent artery and in the free segments of the stent. Thus, patency and neointimal proliferation at covered vessel side branches are influenced by the hemodynamic modification secondary to stent sizing and device porosity [37]. These data need to be interpreted with caution since in clinical practice several studies have reported perforator infarction, especially in the treatment of perforator-rich areas such as A1, M1, and posterior circulation aneurysms [38–41]. For instance, Pistocchi et al. treated 26 patients with 30 IAs beyond the circle of Willis with flow diverters and had three ischemic complications, one permanent and two reversible. Interestingly, they found no permanent neurological deficit in 13 patients with side-branch flow restriction at latest imaging follow-up [42]. More recently, Saleme et al. reported their technical experience with flow diverters for bifurcation aneurysms in the anterior circulation, and they found a 78% (11/14) rate of asymptomatic side-branch narrowing or occlusion when the flow diverter was placed in the anterior communicating artery or internal carotid artery (ICA) bifurcation. The authors have suggested that this phenomenon was due to direct and sufficient collateral supply. On the other hand, they found a 31% (5/16) rate of symptomatic side-branch narrowing or occlusion when flow diverters were placed in anatomical configurations with no direct collateral arterial connection such as in the middle cerebral artery (MCA) bifurcation or beyond the circle of Willis [43]. Briganti et al. reported a similar experience in their case series with MCA aneurysms. They treated 14 patients with 15 MCA aneurysms, in which 13 aneurysms had side branches, and at latest follow-up, only three cases had side-branch occlusion with neurological deficit in two of them [44]. In other European case series, Gawlitza et al. performed a detailed analysis of cortical branches and perforating arteries covered by flow diverters. They treated 17 patients with 18 IAs with a single flow diverter in all cases. Nineteen cortical branches were covered, and at latest follow-up (mean 7.9 months), two were occluded, nine showed a decreased caliber, and the remaining branches were unchanged. Interestingly, none of these patients showed neurological symptoms due to leptomeningeal collateral supply in their cortical territories. On the other hand, symptomatic ischemic events (reversible within 24 h) were seen in three patients with occlusion of perforating arteries and magnetic resonance imaging demonstrated asymptomatic lacunar defects in five patients corresponding to perforating artery territories [38].

Although flow-diversion technology has been introduced relatively recently in the endovascular armamentarium, the sophistication of technology and difficulty in achieving adequate reconstruction of complex aneurysms with endosaccular techniques have established flow diversion as an effective modality of treatment. In fact, it is becoming the first-line treatment option in certain neurovascular centers due to evidence of higher rates of complete aneurysm occlusion independent of lesion morphology as well as lower procedural costs compared to conventional stent-assisted coiling [45–49]. This technology became first available in Europe in 2008 with introduction of the Silk flow diverter (SILK; Balt Extrusion, Montmorency, France) and the Pipeline™ Embolization Device (PED, ev3-Covidien, Irvine, CA, USA) [50,51]. However, the PED is the only US FDA-approved flow diverter in the United States and the most widely used worldwide. The first-generation PED obtained European CE mark in 2008 and FDA approval in 2011 for patients older than 22 years with large or giant wide-necked (≥4 mm or no discernible neck) aneurysms of the ICA from the petrous to the superior hypophyseal segments. The second generation of the PED, known as Pipeline Flex Embolization Device (PED

Flex), preserves the same flow-diverter design, material, and configuration of the previous generation but has a new delivery system that makes it almost completely resheathable [52,53]. It obtained the European CE mark in March 2014 and the FDA approval in February 2015.

3. Pipeline embolization device

The PED is a self-expanding, cylindrically shaped stent, composed of 48 braided strands in a standard pattern. The mesh of the device is composed of 75% chromium–cobalt alloy and 25% radiopaque platinum–tungsten alloy microfilaments. Each strand measures approximately 30 µm in diameter and has a cell size ranging from 0.02 to 0.05 mm. The device has a porosity of 65–75% and when deployed properly it affords 30–35% coverage of the arterial wall surface. It is available in diameters from 2.5 to 5.0 mm, in 0.25-mm increments, and lengths from 10 to 35 mm. It is important to take into account that the real extent of metal coverage varies depending on device size, degree of vessel curvature where the device is implanted, and number of overlapped devices [54]. When the device is fully expanded, its design allows for an opening of 0.25 mm larger than the labeled diameter, and due to its flexibility, it is well suited for tortuous vascular anatomy [34,55]. The second generation of this flow diverter, the PED Flex, maintains the same implements, but the delivery system was completely redesigned in order to reduce the technical difficulties when deploying the device.

3.1. Pipeline Flex delivery system

The new PED delivery system has been introduced to the endovascular armamentarium with high expectations since the rate of complications with the PED Classic has been often associated with deployment of multiple devices, complex maneuvers to proper deployment, and the steep learning curve associated with the deployment technique [54,56–58]. Therefore, this refined delivery system intends to facilitate the device placement and reduce the rate of intraprocedural complications. The PED Flex is mounted by elongation on a stainless steel micro-guidewire approximately 200 cm long and compressed inside an introducer sheath. The delivery wire has a 15-mm soft distal tip with an angle of 55° and a proximal platinum marker for visibility. In the PED Flex delivery system, the distal capture coil has been removed and substituted with two 3-mm protective sleeves of polytetrafluoroethylene. These non-radiopaque sleeves protect the distal portion of the braid while advancing through the microcatheter (Figure 1). In addition, the sleeves allow the device to be released instantly with no need to obtain the classic 'cigar-shape' or torquing maneuvers. The proximal edge of the PED Flex is placed on a 3-mm resheathing pad that allows recapturing and repositioning the device until it has reached nearly 90% deployment, providing a more controlled and precise placement (Figure 2). When the flow diverter is deployed, it expands radially and shortens longitudinally (up to 50–60%), and similar to the PED Classic, its design allows telescoping multiple devices within each other to increase the metal surface coverage or the length of the reconstructed vessel. When device telescoping is anticipated, smaller devices should be deployed first in order for larger flow diverters to expand within the smaller ones. Additionally, telescoping devices increase the metal coverage and porosity of the diseased vessel segment although it increases the risk of procedure-related events and thromboembolic complications [54,59–61].

3.2. Pipeline Flex deployment technique

The high-metal content in the mesh of the PED creates a high risk for thrombus formation and thus patients are routinely started on dual antiplatelet therapy at least 3–7 days prior to the procedure, which typically consists of aspirin (100–325 mg/day) and clopidogrel (75 mg/day). After the procedure, dual-antiplatelet therapy is maintained for 6 months followed by aspirin alone indefinitely. The antiplatelet regimen is decided on a case-by-case basis since some reports have suggested that up to one-third of patients may be resistant to clopidogrel because of genetic polymorphisms [62,63]. Although the platelet function testing with P2Y12 reaction units (PRU) remains controversial [64], the preoperative PRU determination has been highly adopted by neurovascular centers to guide antiplatelet therapy. In our institution in the setting of nonresponse to clopidogrel, patients are treated with ticagrelor [65,66].

The intervention is usually performed under general anesthesia using intravenous heparin systematically to maintain an activated clotting time two times above the patient's baseline or greater than 250 s. A triaxial system is recommended to provide stability and control during flow-diverter deployment. This system typically consists of a proximal 6-French guide catheter, an intermediate catheter that allows additional distal support particularly when the distal arterial anatomy is tortuous, and the delivery microcatheter. Unlike conventional endosaccular embolization, optimal views of the proximal and distal landing zones within the parent artery are paramount and should be obtained from the working-angle

Figure 1. Distal braid opening of the Pipeline™ Flex Embolization Device. (a) The non-radiopaque sleeves protect the distal braid while advancing the device through the microcatheter. (b) The device is released instantly without forming a 'cigar-shape'. (c) Deployment maneuvers are simpler and do not require torquing as in the previous generation. Images courtesy of Medtronic. © Medtronic. All rights reserved.

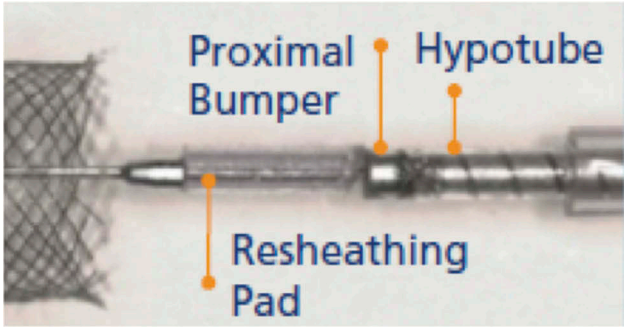

Figure 2. Proximal end of the Pipeline™ Flex embolization device that allows recapturing and repositioning up to approximately 90% deployment. Images courtesy of Medtronic. © Medtronic. All rights reserved.

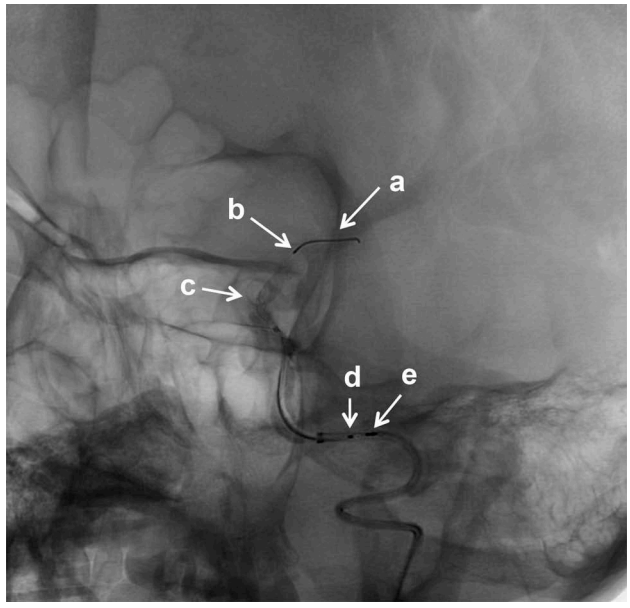

Figure 3. Angiogram in lateral view demonstrates the Pipeline™ Flex delivery system. (a) Coil tip. (b) Distal marker. (c) Partially deployed device. (d) Resheathing marker. (e) Proximal bumper.

angiogram and three-dimensional reconstructions. Once accurate vessel measurements are obtained, the flow diverter is chosen based on the labeled diameter that approximates the diameter of the parent vessel and a length at least 6 mm longer than the aneurysm neck. Ideally, the device should be deployed within normal artery segments. It is important to determine the ideal device since an oversized flow diverter would lead to a decreased metal coverage or a significant mismatch in luminal diameter that may lead to an 'accordion effect' resulting in stent migration [56,67]. The PED Flex was designed to be delivered through a compatible 0.027-inch microcatheter, such as the Marksman (eV3, Irvine, California, USA), and at least 135 cm in length. The microcatheter is navigated under roadmap guidance over a microwire, and the microcatheter tip is placed at least 20 mm beyond the distal edge of the aneurysm neck. The PED Flex system is packaged in an introducer sheath. This sheath is carefully placed into the rotating hemostatic valve, and the system is advanced until the tip of the delivery system is aligned with the tip of the microcatheter. Once they are aligned, the desired location of the PED Flex is confirmed under fluoroscopic guidance. It is recommended that the distal end of the device should be placed at least 3 mm beyond the distal edge of the aneurysm. The deployment process consists of slowly retracting the microcatheter, stabilizing the delivery system (unsheathing), and minimal push of the delivery wire once the device is placed in the desired position (Figure 3). In contrast to the previous PED, this new system does not require a torquing maneuver since the sleeves allow an instant braid release after 10–15 mm of the braid is deployed. Also, the resheathing and redeployment capability of the system allows a safer and more precise placement of the device. This maneuver basically consists of advancing the microcatheter while pulling the delivery wire to retract the PED into the microcatheter. The device can be resheathed until the resheathing marker has reached the distal marker of the microcatheter, and it can be partially or fully resheathed. The operator should be aware that resheathing more than two full cycles might damage the distal end of the braid since the sleeves may either invert or go under the device; thus when pushing through the microcatheter to redeploy the device, the distal edge is unprotected and it can be damaged during the maneuver. Occasionally, when resheathing the device, the operator may feel resistance when repositioning it, and this can be caused by a partial opening of the sleeves and can be resolved by advancing the microcatheter to fully invert the flaps (*inverting flaps maneuver)*. Once the PED Flex is deployed, the microcatheter is carefully advanced through the flow diverter until the microcatheter tip is distal to the reconstruction, and the delivery microwire is recaptured. Finally, the wall apposition of the device is confirmed under fluoroscopy, and if an endoleak is detected, it should be addressed by the J-wire technique or balloon angioplasty to fully open the device. A conventional angiogram is performed to evaluate flow of contrast material into the aneurysm, and ideally, contrast stasis should be immediately seen within the aneurysm if the device is well apposed across the neck (Figure 4). However, in case of persistent inflow, additional devices may be telescoped as needed in order to increase metal coverage of the diseased vessel segment. After the device is deployed, coiling the aneurysm is no longer possible, and for that reason, the jailing technique should be performed if adjunctive coiling is necessary. There is still considerable debate regarding adjunctive coiling for giant aneurysms since several studies have shown no prevention of aneurysm rupture, which can result in catastrophic events [68–72]. Possible mechanisms attributed to this phenomenon consist of an increase in the pressure of the sac producing more stress on the aneurysm wall, non-homogenous coil packing, and a rapid accumulation of macrophages producing lytic enzymes resulting in an aggressive autolytic effect of the thrombus and destruction of the aneurysm wall. Therefore, the treatment of this subset of lesions should be done on case-by-case basis. Possible solutions consist of increasing neck coverage with multiple devices, resulting in a more stable mesh density, adjunctive coiling with immediate flow-diverter placement or in a delayed fashion, or other treatment modality such as parent vessel sacrifice.

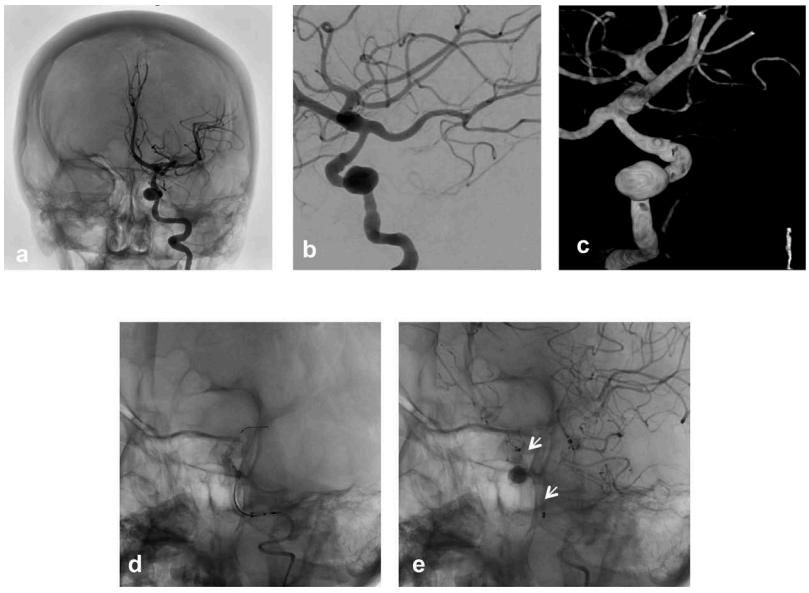

Figure 4. Case illustration. Female in her 30 s presented with visual disturbances and (a-b) digital subtraction angiography (DSA) demonstrated a left paraclinoid aneurysm. (c) 3-D reconstruction depicting the aneurysm. (d) Deployment of the Pipeline™ Flex Embolization Device across the aneurysm. (E) DSA demonstrating contrast stasis inside the aneurysm after placing 2 devices. Arrows show the reconstructed segment of the parent vessel.

4. Clinical experience with the Pipeline embolization device

4.1. Clinical experience with the Pipeline Classic embolization device

The clinical experience with the PED Classic has been widely reported, demonstrating its safety and efficacy in the treatment of aneurysms independently of lesion morphology [73,74]. The first prospective experience took place in Argentina where the authors reported an aneurysm occlusion rate of 92.8% at 6 months after treating 53 patients with 63 aneurysms [48]. Subsequently, Szikora et al. reported the first experience in Europe with an aneurysm occlusion rate of 89.5% at 6 months after intervening in 18 patients with 19 aneurysms [75]. More recently, two breakthrough clinical trials demonstrated similar results: the PED for the intracranial treatment of aneurysms (PITA) and the Pipeline for uncoilable or failed aneurysms (PUFS). The PITA trial was performed with the participation of three European and one South American centers. They reported an aneurysm occlusion rate of 93.3% at 6 months after treating 31 consecutive patients with 31 aneurysms and 2 periprocedural strokes [55]. The PUFS trial was a multicenter single-arm study conducted at eight sites in the USA and two sites outside the USA that enrolled 108 patients with 108 aneurysms in the ICA. They reported an aneurysm occlusion rate of 73.6% at 6 months and six major neurological events [46]. The results of the PUFS trial granted the FDA approval to the PED. Chiu et al. have recently demonstrated long-term durability of the aneurysm occlusion in 98 patients with 119 wide-necked aneurysms treated with the PED in Australia. The median radiographic follow-up was 26 months, and the longest follow-up reported was 56 months. The aneurysm occlusion rate progressed from 81.6% at 6 months to 93.2% at final follow-up. It is important to point out that they found only seven persistent aneurysms at final follow-up, and three of them were associated with a vessel in the dome or neck of the lesion [76]. Due to the report of severe complications in small case series and meta-analysis showing a morbidity rate ranging from 5% to 7.3% and a mortality rate ranging from 2.8% to 4% [73,74], the International Retrospective Study of the Pipeline Embolization Device (IntrePED) registry was designed to determine clinical outcomes and rate of complications in a 'real-world' setting. A total of 793 patients with 906 aneurysms from 6 countries at 17 centers were included in the analysis, and 824 out of 906 aneurysms (91%) were unruptured, and only 95 (10.5%) were located in the posterior circulation. The median follow-up was 19.3 months. They found a 30-day neurological morbidity rate of 5.7% (45/793) and a 30-day mortality rate of 2.8% (22/793), with the highest combined percentage of neurological morbidity and mortality in the non-ICA anterior circulation group (13.4%) and the lowest in the ICA group with aneurysm size <10 mm (4.1%). Specifically, they found an ischemic stroke rate of 4.5% (36/793), an intracranial hemorrhage rate of 2.5% (20/793), an in-stent stenosis rate of 0.3% (2/793), and permanent cranial neuropathy rate of 0.3% (2/793) [45]. A subanalysis of the IntrePED study was performed to evaluate the risk factors for postoperative acute ischemic complications. They found, based on logistic regression analysis, that the variables associated with an increased risk of having the events were male sex, hypertension, treatment of MCA aneurysms, giant aneurysms, fusiform aneurysms, and the use of multiple PEDs. Treatment of fusiform aneurysms was the only variable independently associated with an increased risk of postoperative ischemic stroke after performing multivariate logistic regression analysis (2.74, 95% CI: 1.11–6.75, $p < 0.05$). It is noteworthy that 72.2% (22/36) of ischemic events occurred within a 30-day period of treatment [77]. Other subanalysis of the IntrePED study showed that patients older than 70 years undergoing PED placement had an increased risk of

neurological mortality (7.4%) and all-cause mortality (8.3%) when compared with younger patients. However, interpretation of the results requires care since other comorbidities are generally increased with older age. Regarding overall complications, the authors found no differences between groups. Therefore, we strongly agree with the authors that age alone should not be considered as an exclusion criterion for the treatment of unruptured aneurysms with the PED, and the decision should be done on a case-by-case basis [78]. One of the main concerns when treating an aneurysm with the PED is the continued risk of aneurysm rupture, and unlike the recommendation of adjunctive coiling when using the SILK [79], the use of coils with the PED is left to discretion of the operator. However, the safety and efficacy of this adjunctive therapy with the PED are not well known. Based on the results of the IntrePED study subanalysis, 109 aneurysms were treated with adjunctive coil. They found increased procedure time in the group treated with PED and coils compared with the PED-alone group (135.8 ± 63.9 min versus 96.7 ± 46.2 min, $p < 0.05$). According to their results, the decision to treat patients with the PED and coils was highly influenced by the aneurysm size since the aneurysms treated with the PED alone were slightly smaller (13.6 ± 7.8 mm versus 10.3 ± 7.6 mm, $p < 0.05$). It is important to note that due to the retrospective nature of the study, procedures and decisions varied across centers; therefore, adjunctive coiling or overlapping PEDs were based on the physician's judgment and not per protocol. In addition, they found no significant differences in major complications between groups although the neurological combined morbidity and mortality rate was higher in the group with PED and coils compared with the PED-alone group, 12.5% versus 7.8%, respectively [80]. Thus, this study illustrates that in spite of increased procedure time, technical complexity, and endosaccular manipulation, the overall rate of complications remains low with either embolization strategy.

Recently, the results of the Aneurysm Study of Pipeline in an Observational Registry were published [81]. This multicenter registry included patients with unruptured IAs treated with PED over a 3-year period in 28 centers in seven countries and aimed to prospectively analyze the rates of aneurysm occlusion and neurological adverse events following the intervention. A total of 191 patients with 207 aneurysms were included with a median imaging follow-up of 7.8 months and a median clinical follow-up of 6.2 months. The neurological morbidity rate was 6.8% (13/191), ischemic stroke was the most common event in 4.7% of patients (9/191), and the neurological mortality rate was 1.6% (3/191). Regarding aneurysm occlusion, imaging was available in 103 subjects at 6 months, and 74.8% achieved a complete aneurysm occlusion. Interestingly, only 5.8% of patients required retreatment over the study period, and spontaneous aneurysm rupture was a rare event that occurred in 1.6% of patients. This study confirmed the findings of previous PED studies regarding safety and efficacy in a postmarketing setting.

4.2. Clinical experience with the Pipeline Flex embolization device

Although mid- and long-term results are expected to be similar with the PED Flex in comparison with the previous PED generation, the safety and efficacy of the new delivery system is still unknown, and recent prospective series show promising technical and clinical results (Table 1). Martinez-Galdamez et al. reported the first experience with this device in Spain to treat six consecutive patients with six unruptured aneurysms, one of them located in the posterior circulation [60]. They had no intraprocedural complications, and all devices were successfully deployed. They reported resheathing and repositioning of the device in two cases. Pereira et al. reported the second experience with the device in the treatment of 12 unruptured saccular aneurysms in 10 patients. They successfully deployed 12 flow diverters with no intraprocedural complications, and repositioning was required in five cases. Coiling was performed in two cases before device implantation [59]. The first use of the PED Flex in the USA aimed to treat an unruptured symptomatic large posterior inferior cerebellar artery aneurysm. Due to the complex aneurysm and location, Duckworth et al. rehearsed the procedure on a vascular-replication system model of the patient. The final procedure consisted of a successful device deployment with adjunctive coiling. Although the patient reported intermittent headaches postprocedure, at 3-month follow-up, she was neurologically stable and the angiogram demonstrated almost complete thrombosis of the aneurysm [52]. Martinez-Galdamez et al. reported the first multicenter experience in Europe, treating 30 consecutive patients in nine academic centers in Spain. A total of 30 patients harboring 30 IAs were intervened during a 3-month period. Thirty-nine devices were deployed, resulting in an average of 1.3 flow diverters per case. They reported a resheathing maneuver in 11 cases due to a partial opening of the device, as well as recapture maneuver in five cases for a better wall apposition and in four cases due to migration/malposition of the device. At 30-day follow-up, they reported two major neurological complications (6.6%), consisting of ischemic infarcts involving the anterior choroidal arteries where two devices were overlapped [82]. To date, Colby et al. have published the largest series of patients treated with the PED Flex in North America. They consecutively intervened in 42 patients with 44 IAs in a 3-month period with 93% (41/44) of the aneurysms located in the anterior circulation. The device was successfully placed in 98% of the cases. A single PED was used in 41 cases, resheathing was reported in four, and they had no intraprocedural complications. The rate of postprocedure neurological complications was 2.3%, with one ischemic stroke as a consequence of in-stent thrombosis in a patient noncompliant with antiplatelet medications [53]. Le et al. reported the first comparison between patients treated with the PED Classic and PED Flex. They retrospectively analyzed the outcomes of 58 PED Classic cases versus 38 PED Flex cases. Both groups had similar characteristics with exception of aneurysm size that was slightly smaller in the PED Flex cases. They found that the use of PED Flex reduced significantly the total procedure time, fluoroscopy time, patient radiation exposure, contrast usage, and rate of deployment failure compared with PED Classic. The aforementioned differences were attributed to the resheathing capacity of the PED Flex. However, they found no difference in intraprocedural events or neurological deficits between groups [83]. The current experience with the PED Flex is limited, but initial results strongly suggest its safety and short-term efficacy.

Table 1. Clinical experience with the Pipeline Flex Embolization Device.

Case series (years)	Study design	*N/n*	Anterior/ posterior circulation	Mean aneurysm size (range), mm	Aneurysm morphology (saccular/fusiform/ dissecting/segmental defect)	No. of PED Flex	No. of PED Flex per aneurysm	Successful deployment (%)	Resheath/ reposition (cases)	Intraprocedural complications/events	30-Day morbidity	Reference
Martinez-Galdamez et al. (2014)	Prospective	6/6	5/1	11.5 (4–30)	4/0/2/0	8	1.3	8 (100)	2	None	-	[60]
Pereira et al. (2014)	Prospective	10/12	12/0	11 (3–16)	9/0/0/3	11	1[a]	11 (100)	5	None	-	[59]
Duckworth et al. (2015)	Case report	1/1	0/1	Large[b]	1 (saccular)	1	1	1 (100)	1	None	None	[52]
Martinez-Galdamez et al. (2015)	Prospective	30/30	28/2	21.3 (2–30)	23/1/3/3	39	1.3	39 (100)	4	One vessel-branch occlusion of the MCA, resolvedOne in-stent thrombosis resolved. Partial opening resolved with resheathing maneuver and reopen	6.6% (2/ 30)	[82]
Colby et al. (2015)	Prospective	42/44	41/3	6.5 (3–22)	36/6/2/0	45	1.07	43 (98)	4	One postprocedure groin hematoma and femoral pseudoaneurysm One major neurological complication	-	[53]
Le et al. (2016)[c]	Retrospective	38/46	43/3	4.3 (1.8–7.4)	Not described	42	1.03	39 (92.9)	Not reported	One postprocedure neurological event	-	[83]

N: number of patients; *n*: number of aneurysms; No.: number; PED: Pipeline embolization device; MCA: middle cerebral artery.
[a]A PED Classic was used (short size not available in PED Flex).
[b]The aneurysm size was not reported, and adjunctive coiling was used.
[c]Study comparing procedural outcomes between PED Classic and PED Flex.

5. Expert commentary

The introduction of flow diverters in the neuroendovascular armamentarium has made a revolutionary change in the treatment of IAs, mainly those with complex anatomical morphology. This technology has allowed us to treat lesions that would be otherwise challenging for surgical clipping or unsuitable for other endosaccular strategies. Since the introduction of the PED in 2011, the data published demonstrating its safety and efficacy are enormous with excellent aneurysm occlusion rates at mid-term and long term and low rates of recanalization. Not surprisingly, flow diversion has been highly adopted worldwide. Moreover, with the redefined delivery system of the second-generation PED, outcomes are expected to be similar or better than the previous-generation PED. At this point, the existing data are scant in terms of long-term outcomes but supports an adequate technical profile. We find that the capacity of resheathing and repositioning the device definitely makes a less problematic deployment as well as allows safer bailout techniques avoiding maneuvers that were considered complex to deploy the PED Classic. Therefore, we believe that the learning curve will not be challenging for the interventionalist familiar with the PED Classic, but formal training should be warranted in order to reduce complications and get competent with the new technical adaptations of the PED Flex.

The PED Classic has offered a well-suited option to treat aneurysms that has attracted the interest to evaluate the cost-effectiveness in comparison with other endovascular therapies. Results across studies are not consistent, some of them favor flow diverters over traditional endosaccular modalities but others show the opposite. However, the benefit is clear in terms of length of hospital stay and cost savings for unruptured aneurysms [49,84–87]. To date, there is no formal study evaluating cost-effectiveness with the PED Flex, but the current trend shows a reduction in the number of deployed devices, and also with the continuous introduction of flow diverters in the market, we expect a reduction in the cost of each device.

The lessons learned from the PED Classic data should guide better strategies, better clinical judgment, and more predictable outcomes when deciding to use the PED Flex. For instance, Shapiro et al. have recently published an excellent analysis of their case series regarding failure of progression to aneurysm occlusion after embolization with the PED. They included patients with a 1-year angiography follow-up and found that risk factors predisposing aneurysm non-occlusion were preexisting stents, fusiform aneurysm morphology, branch vessel runoff, and technical events such as endoleaks [88]. This reflects that a better understanding of the flow-diverter properties, further operator experience, and longer follow-ups are contributing to the development of refinements in technology to overcome difficulties and treat the most challenging IAs. Lastly, the decision to use a flow diverter in the treatment of an aneurysm should be taken in a case-by-case basis weighing comorbidities and the risk of ischemic or hemorrhagic events.

6. Five-year view

The neurointerventional field is constantly evolving with the development of innovative devices and less invasive techniques. Flow-diversion technology has made a paradigm shift, and the development of devices has rapidly increased despite of their recent introduction. To date, the experience with the PED Flex delivery system is limited to small case series of retrospective or prospective design since its introduction in 2014. However, the studies mentioned above strongly suggest an improved handling and deployability of the PED Flex in comparison with the previous generation. So far, the data show a trend in the reduction of intraprocedural complications, procedure time, and number of devices deployed. Long-term outcomes will be required to draw final conclusions, especially regarding the incidence of delayed ruptured aneurysm, stent migration, and bifurcation-type aneurysms. The off-label experience with the PED Classic has been highly reported in small series, but results vary from low to high rate of complications depending on anatomical location, lesion morphology, and clinical presentation. Outcomes seem promising in high-volume centers with a careful patient selection [89–93]. Although the PED Flex is only cleared to treat large or giant unruptured wide-necked aneurysms in the ICA, it is clear that in the coming years, there will be an expansion of indications because its delivery system might facilitate the treatment of smaller aneurysms, posterior circulation aneurysms, distal anterior circulation aneurysms (Figure 5), blisters aneurysms, and even ruptured aneurysms. Furthermore, with advances in technology, a future iteration of the PED based on a modified phosphorylcholine structure is under development, which may reduce or eliminate the need of antiplatelet therapy [94]. However, the question will be if modifying the structure of the PED would yield the successful results obtained so far.

Currently, the medical literature offers initial and promising experience with several flow diverters, and although these devices share the same mechanism of action, they vary in braid design and deployment technique. The SILK was the first flow diverter available composed of 48 braided nitinol strands with a high rate of aneurysm occlusion and a low rate of periprocedural complications [95]. The Surpass flow diverter (Stryker Neurovascular, Fremont, CA, USA) has a single-layer mesh that maintains a constant porosity across all sizes available. This feature is expected to reduce the need of telescoping devices [96–100]. The Flow Re-direction Endoluminal Device (FRED; MicroVention, Tustin, CA, USA) has a unique double-layer mesh design. It consists of a low-porosity inner mesh and a high-porosity outer stent. The dual-layer system offers an improved scaffolding effect as well as full-stent length fluoroscopic visualization [101–105]. The p64 (Phenox, Bochum, Germany) received the European CE mark in 2012. This flow diverter consists of a 64 nickel–titanium (nitinol)-braided mesh with a unique system, which allows the operator to fully retrieve it even after complete deployment [106–108]. The Derivo Embolization Device is a new flow diverter that has been tested in elastase-induced aneurysms in rabbits. It is a 48-nitinol-

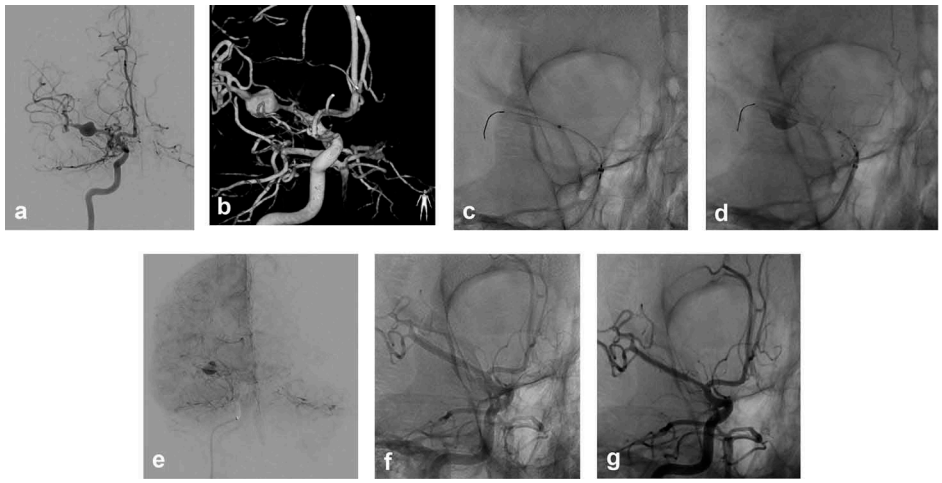

Figure 5. Female patient in her 20 s presented with headache. Diagnostic digital subtraction angiography (DSA) demonstrated a right fusiform dissecting aneurysm in the M1 segment of the middle cerebral artery (MCA). (a) Right MCA, anteroposterior view; (b) Right MCA, 3-D reconstruction of the fusiform aneurysm; (c) Deployment of the Pipeline™ Flex Embolization Device (PED Flex) in the right MCA; (d) A second PED Flex was deployed to appropriately cover normal artery segments; (e) DSA demonstrated delayed contrast stasis after the second PED Flex was placed in the diseased vessel segment. At 6-month follow-up, (f) DSA shows endoluminal reconstruction of the MCA with 2 PED Flex and (g) demonstrates no recurrence or residual aneurysm.

Table 2. Summary of new flow diverters and recent outcomes.

	SURPASS	FRED	p64
Flow-diverter design	Cobalt–chromium and platinum wires (48, 72, 96 braided wires)	Dual layer: low-porosity inner mesh (48 nitinol wires) and high-porosity outer mesh (16 nitinol wires)	64 nickel–titanium (nitinol)-braided mesh
Resheathability (%)	75–80	75–85	100
Number of publications[a]	5	5	3
Patients (aneurysms)	220 (257)	101 (117)	166 (186)
Neurological morbidity (%)[b]	0–10.4	0–11	0–6.7
Mortality (%)	0–2.7	0	0–0.8%
Complete aneurysm occlusion (%)[c]	75–100	73–100	85.7–88
References	[96–100]	[101–105]	[106–108]

SURPASS: Surpass flow diverter; FRED: Flow Re-direction Endoluminal Device.
[a]Search terms: surpass flow diverter, FRED flow diverter, p64 flow diverter. Data include single case reports. Date: 12 August 2016.
[b]Range of transient and permanent neurological morbidity in case series.
[c]Range of complete aneurysm occlusion based on latest imaging follow-up in case series.

braided mesh with a 65% of porosity and can be retrieved after up to 90% deployment. Preclinical results seem promising with its unique surface made of BlueXide that is less reactive and leads to higher surface density and smoothness [109]. These devices demonstrate the rapid phase of innovation that we are living in our field and the need to have reliable data to translate into physician's decision and patient care (Table 2). Therefore, the neurointerventionalist should balance the new technology with current available tools to treat aneurysms, and we consider that the establishment of multicenter prospective registries of patients treated with flow diverters would increase the accuracy of data in a 'real-world setting' as well as the reduction in underreporting periprocedural complications, since not every situation is ideal to perform a randomized clinical trial due to lack of adequate control, loss of equipoise, or delay in the progress of technology in our field.

7. Conclusions

The current treatment of IAs targets the reduction in the incidence of spontaneous rupture and alleviating the symptoms of mass effect either with surgery or with endovascular modalities. Flow-diversion technology has become an effective and safe option with a high rate of aneurysm occlusion and a low rate of morbidity and mortality. The PED Flex is a novel tool with a redefined delivery system that allows a more precise and safer placement of the flow diverter. Recent clinical studies support its safe technical profile. However, further research and clinical experience will offer final conclusions and the possibility to extend its application to other aneurysm settings.

Key issues

- Flow diversion technology has expanded the neuroendovascular options for treatment of intracranial aneurysms and has become a viable monotherapy option to address lesions with complex morphology that were unsuitable for surgical clipping or traditional endovascular strategies.
- The first-generation Pipeline™ Embolization Device has demonstrated its safety and efficacy worldwide in large prospective and retrospective studies offering excellent outcomes at mid- and long-term.

- The delivery system of the new Pipeline™ Flex Embolization Device has the capacity of resheathing and/or repositioning the device, with the aim to overcome the deployment difficulties seen in the previous generation.
- The lessons learned from the PED classic data should guide better strategies for aneurysm treatment and patient selection with the PED Flex.

Acknowledgments

The authors thank Suzanne LaScalza, Manish S. Gupta, and Kurt Haggstrom, from Medtronic, for their technical review of the PED Flex features described in this manuscript as well as their assistance with pictures of the device to illustrate the article.

Funding

This paper was not funded.

Declaration of interest

R. Hanel is a Consultant for Covidien, Stryker, Codman, and Microvention; stock ownership in Blockade, and scientific advisory board for Medina Medical. The authors have no other relevant affiliations or financial involvement with any organization or entity with a financial interest in or financial conflict with the subject matter or materials discussed in the manuscript apart from those disclosed.

ORCID

Pedro Aguilar-Salinas http://orcid.org/0000-0002-5268-6548
Leonardo B.C. Brasiliense http://orcid.org/0000-0003-4220-715X
Douglas Gonsales http://orcid.org/0000-0001-8552-2534
Eric Sauvageau http://orcid.org/0000-0003-4399-1142

References

Papers of special note have been highlighted as either of interest (•) or of considerable interest (••) to readers.

1. Frösen J, Tulamo R, Paetau A, et al. Saccular intracranial aneurysm: pathology and mechanisms. Acta Neuropathol. 2012;123(6):773–786.
2. Caranci F, Briganti F, Cirillo L, et al. Epidemiology and genetics of intracranial aneurysms. Eur J Radiol. 2013;82(10):1598–1605.
3. Vlak MH, Algra A, Brandenburg R, et al. Prevalence of unruptured intracranial aneurysms, with emphasis on sex, age, comorbidity, country, and time period: a systematic review and meta-analysis. Lancet Neurol. 2011;10(7):626–636.
4. Connolly ES Jr., Rabinstein AA, Carhuapoma JR, et al. Guidelines for the management of aneurysmal subarachnoid hemorrhage: a guideline for healthcare professionals from the American Heart Association/American Stroke Association. Stroke. 2012;43(6):1711–1737.
5. Nieuwkamp DJ, Setz LE, Algra A, et al. Changes in case fatality of aneurysmal subarachnoid haemorrhage over time, according to age, sex, and region: a meta-analysis. Lancet Neurol. 2009;8(7):635–642.
6. Dandy WE. Intracranial aneurysm of the internal carotid artery: cured by operation. Ann Surg. 1938;107(5):654–659.
7. Guglielmi G, Vinuela F, Sepetka I, et al. Electrothrombosis of saccular aneurysms via endovascular approach. Part 1: electrochemical basis, technique, and experimental results. J Neurosurg. 1991;75(1):1–7.
8. Guglielmi G, Vinuela F, Dion J, et al. Electrothrombosis of saccular aneurysms via endovascular approach. Part 2: preliminary clinical experience. J Neurosurg. 1991;75(1):8–14.
9. Spetzler RF, McDougall CG, Zabramski JM, et al. The barrow ruptured aneurysm trial: 6-year results. J Neurosurg. 2015;123(3):609–617.
   - **Six-year results of the Barrow Ruptured Aneurysm trial demonstrating better outcomes of endovascular coiling in the treatment of intracranial aneurysms, especially in the posterior circulation, when compared to surgical clipping.**
10. Molyneux AJ, Birks J, Clarke A, et al. The durability of endovascular coiling versus neurosurgical clipping of ruptured cerebral aneurysms: 18 year follow-up of the UK cohort of the International Subarachnoid Aneurysm Trial (ISAT). Lancet. 2015;385(9969):691–697.
   - **Eighteen-year results of the ISAT trial demonstrating better survival outcomes of endovascular coiling in the treatment of ruptured intracranial aneurysms when compared to surgical clipping**
11. Piotin M, Pistocchi S, Bartolini B, et al. Intracranial aneurysm coiling with PGLA-coated coils versus bare platinum coils: long-term anatomic follow-up. Neuroradiology. 2012;54(4):345–348.
12. Shapiro M, Becske T, Sahlein D, et al. Stent-supported aneurysm coiling: a literature survey of treatment and follow-up. AJNR Am J Neuroradiol. 2012;33(1):159–163.
13. Coley S, Sneade M, Clarke A, et al. Cerecyte coil trial: procedural safety and clinical outcomes in patients with ruptured and unruptured intracranial aneurysms. AJNR Am J Neuroradiol. 2012;33(3):474–480.
14. Hong Y, Wang Y-J, Deng Z, et al. Stent-assisted coiling versus coiling in treatment of intracranial aneurysm: a systematic review and meta-analysis. PLoS One. 2014;9(1):e82311.
15. King B, Vaziri S, Singla A, et al. Clinical and angiographic outcomes after stent-assisted coiling of cerebral aneurysms with Enterprise and Neuroform stents: a comparative analysis of the literature. J Neurointerv Surg. 2015;7(12):905–909.
   - **Systematic review of recent publications in the treatment of intracranial aneurysms with stent-assisted coiling embolization.**
16. Raymond J, Guilbert F, Weill A, et al. Long-term angiographic recurrences after selective endovascular treatment of aneurysms with detachable coils. Stroke. 2003;34(6):1398–1403.
17. Cottier JP, Pasco A, Gallas S, et al. Utility of balloon-assisted Guglielmi detachable coiling in the treatment of 49 cerebral aneurysms: a retrospective, multicenter study. AJNR Am J Neuroradiol. 2001;22(2):345–351.
18. Katsaridis V, Papagiannaki C, Violaris C. Embolization of acutely ruptured and unruptured wide-necked cerebral aneurysms using the neuroform2 stent without pretreatment with antiplatelets: a single center experience. AJNR Am J Neuroradiol. 2006;27(5):1123–1128.
19. Maldonado IL, Machi P, Costalat V, et al. Neuroform stent-assisted coiling of unruptured intracranial aneurysms: short- and midterm results from a single-center experience with 68 patients. AJNR Am J Neuroradiol. 2011;32(1):131–136.
20. Sani S, Jobe KW, Lopes DK. Treatment of wide-necked cerebral aneurysms with the Neuroform2 Treo stent. A prospective 6-month study. Neurosurg Focus. 2005;18(2):1–5.
21. Vendrell J-F, Costalat V, Brunel H, et al. Stent-assisted coiling of complex middle cerebral artery aneurysms: initial and midterm results. AJNR Am J Neuroradiol. 2011;32(2):259–263.
22. Weber W, Bendszus M, Kis B, et al. A new self-expanding nitinol stent (Enterprise) for the treatment of wide-necked intracranial aneurysms: initial clinical and angiographic results in 31 aneurysms. Neuroradiology. 2007;49(7):555–561.
23. Bartolini B, Blanc R, Pistocchi S, et al. "Y" and "X" stent-assisted coiling of complex and wide-neck intracranial bifurcation aneurysms. AJNR Am J Neuroradiol. 2014;35(11):2153–2158.
24. Heller RS, Rahal JP, Malek AM. Y-Stent embolization technique for intracranial bifurcation aneurysms. J Clin Neurosci. 2014;21(8):1368–1372.

25. Spiotta AM, Gupta R, Fiorella D, et al. Mid-term results of endovascular coiling of wide-necked aneurysms using double stents in a Y configuration. Neurosurgery. 2011;69(2):421–429.
26. Geremia G, Haklin M, Brennecke L. Embolization of experimentally created aneurysms with intravascular stent devices. AJNR Am J Neuroradiol. 1994;15(7):1223–1231.
27. Wakhloo AK, Schellhammer F, de Vries J, et al. Self-expanding and balloon-expandable stents in the treatment of carotid aneurysms: an experimental study in a canine model. AJNR Am J Neuroradiol. 1994;15(3):493–502.
28. Doerfler A, Wanke I, Egelhof T, et al. Double-stent method: therapeutic alternative for small wide-necked aneurysms. Technical note. J Neurosurg. 2004;100(1):150–154.
29. Seong J, Wakhloo AK, Lieber BB. In vitro evaluation of flow diverters in an elastase-induced saccular aneurysm model in rabbit. J Biomech Eng. 2007;129(6):863–872.
30. Lieber BB, Livescu V, Hopkins LN, et al. Particle image velocimetry assessment of stent design influence on intra-aneurysmal flow. Ann Biomed Eng. 2002;30(6):768–777.
31. Aurboonyawat T, Blanc R, Schmidt P, et al. An in vitro study of silk stent morphology. Neuroradiology. 2011;53(9):659–667.
32. Sadasivan C, Cesar L, Seong J, et al. An original flow diversion device for the treatment of intracranial aneurysms: evaluation in the rabbit elastase-induced model. Stroke. 2009;40(3):952–958.
33. Wakhloo AK, Tio FO, Lieber BB, et al. Self-expanding nitinol stents in canine vertebral arteries: hemodynamics and tissue response. AJNR Am J Neuroradiol. 1995;16(5):1043–1051.
34. Fiorella D, Lylyk P, Szikora I, et al. Curative cerebrovascular reconstruction with the Pipeline embolization device: the emergence of definitive endovascular therapy for intracranial aneurysms. J Neurointerv Surg. 2009;1(1):56–65.
• **Excellent review of the flow-diversion technology and the emergence of the Pipeline embolization device.**
35. Kallmes DF, Ding YH, Dai D, et al. A new endoluminal, flow-disrupting device for treatment of saccular aneurysms. Stroke. 2007;38(8):2346–2352.
36. Kallmes DF, Ding YH, Dai D, et al. A second-generation, endoluminal, flow-disrupting device for treatment of saccular aneurysms. AJNR Am J Neuroradiol. 2009;30(6):1153–1158.
37. Berg P, Iosif C, Ponsonnard S, et al. Endothelialization of over- and undersized flow-diverter stents at covered vessel side branches: an in vivo and in silico study. J Biomech. 2016;49(1):4–12.
• **Excellent *in vitro* analysis of the endothelialization in flow diverters and the consequences of blood flow in vessel side branches and perforators.**
38. Gawlitza M, Januel AC, Tall P, et al. Flow diversion treatment of complex bifurcation aneurysms beyond the circle of Willis: a single-center series with special emphasis on covered cortical branches and perforating arteries. J Neurointerv Surg. 2016;8(5):481–487..
• **Excellent analysis in the treatment of bifurcation aneurysms and analysis of covered cortical branches and perforating arteries**
39. Peschillo S, Caporlingua A, Cannizzaro D, et al. Flow diverter stent treatment for ruptured basilar trunk perforator aneurysms. J Neurointerv Surg. 2016;8(2):190–196.
40. Daou B, Valle-Giler EP, Chalouhi N, et al. Patency of the posterior communicating artery following treatment with the Pipeline embolization device. J Neurosurg. 2016 May 6;1–6. doi:10.3171/2016.2.JNS152544. [Epub ahead of print].
41. Siddiqui AH, Abla AA, Kan P, et al. Panacea or problem: flow diverters in the treatment of symptomatic large or giant fusiform vertebrobasilar aneurysms. J Neurosurg. 2012;116(6):1258–1266.
•• **Recent clinical study demonstrating the difficulties, complications, and adjunctive therapies when treating large or giant aneurysms with flow diverters.**
42. Pistocchi S, Blanc R, Bartolini B, et al. Flow diverters at and beyond the level of the circle of Willis for the treatment of intracranial aneurysms. Stroke. 2012;43(4):1032–1038.
43. Saleme S, Iosif C, Ponomarjova S, et al. Flow-diverting stents for intracranial bifurcation aneurysm treatment. Neurosurgery. 2014;75(6):623-631;quiz 631.
44. Briganti F, Delehaye L, Leone G, et al. Flow diverter device for the treatment of small middle cerebral artery aneurysms. J Neurointerv Surg. 2016;8(3):287–294.
45. Kallmes DF, Hanel R, Lopes D, et al. International retrospective study of the Pipeline embolization device: a multicenter aneurysm treatment study. AJNR Am J Neuroradiol. 2015;36(1):108–115.
•• **Recent international study demonstrating the low rate of complications and combined morbidity and mortality with the use of Pipeline embolization device in the treatment of intracranial aneurysms. Erratum is published.**
46. Becske T, Kallmes DF, Saatci I, et al. Pipeline for uncoilable or failed aneurysms: results from a multicenter clinical trial. Radiology. 2013;267(3):858–868.
•• **Recent clinical trial demonstrating the safety and efficacy of the Pipeline embolization device at 6 months.**
47. Gross BA, Frerichs KU. Stent usage in the treatment of intracranial aneurysms: past, present and future. J Neurol Neurosurg Psychiatry. 2013;84(3):244–253.
48. Lylyk P, Miranda C, Ceratto R, et al. Curative endovascular reconstruction of cerebral aneurysms with the Pipeline embolization device: the Buenos Aires experience. Neurosurgery. 2009;64(4):632-642; discussion 642-633; quiz N636.
•• **First case series published in Latin America in the treatment of intracranial aneurysms with the Pipeline embolization device.**
49. Colby GP, Lin LM, Paul AR, et al. Cost comparison of endovascular treatment of anterior circulation aneurysms with the Pipeline embolization device and stent-assisted coiling. Neurosurgery. 2012;71(5):944–948;discussion 948–950.
50. Leonardi M, Dall'olio M, Princiotta C, et al. Treatment of carotid siphon aneurysms with a microcell stent. A case report. Interv Neuroradiol. 2008;14(4):429–434.
51. Alghamdi F, Morais R, Scillia P, et al. The Silk flow-diverter stent for endovascular treatment of intracranial aneurysms. Expert Rev Med Devices. 2015;12(6):753–762.
52. Duckworth EA, Nickele C, Hoit D, et al. The first North American use of the Pipeline Flex flow diverter. J Neurointerv Surg. 2016 Feb;8(2):e8. doi:10.1136/neurintsurg-2014-011548.rep. Epub 2015 Feb 4.
53. Colby GP, Lin LM, Caplan JM, et al. Immediate procedural outcomes in 44 consecutive Pipeline Flex cases: the first North American single-center series. J Neurointerv Surg. 2016 Jul;8(7):702–709. doi:10.1136/neurintsurg-2015-011894. Epub 2015 Jul 1.
• **Recent clinical study in the USA demonstrating the initial outcomes of the Pipeline Flex embolization device in the treatment of intracranial aneurysms.**
54. Shapiro M, Raz E, Becske T, et al. Variable porosity of the Pipeline embolization device in straight and curved vessels: a guide for optimal deployment strategy. AJNR Am J Neuroradiol. 2014;35(4):727–733.
• **Excellent analysis of the variability in porosity of the Pipeline embolization device and deployment strategies in curved vessels.**
55. Nelson PK, Lylyk P, Szikora I, et al. The Pipeline embolization device for the intracranial treatment of aneurysms trial. AJNR Am J Neuroradiol. 2011;32(1):34–40.
•• **Recent clinical trial demonstrating the safety and efficacy of the outcomes of the Pipeline embolization device.**
56. Chalouhi N, Tjoumakaris SI, Gonzalez LF, et al. Spontaneous delayed migration/shortening of the Pipeline embolization device: report of 5 cases. AJNR Am J Neuroradiol. 2013;34(12):2326–2330.
57. Jabbour P, Chalouhi N, Tjoumakaris S, et al. The Pipeline embolization device: learning curve and predictors of complications and aneurysm obliteration. Neurosurgery. 2013;73(1):113-120;discussion 120.
58. Park MS, Albuquerque FC, Nanaszko M, et al. Critical assessment of complications associated with use of the Pipeline embolization device. J Neurointerv Surg. 2015;7(9):652–659.

59. Pereira VM, Kelly M, Vega P, et al. New Pipeline Flex device: initial experience and technical nuances. J Neurointerv Surg. 2015;7(12):920–925.
• **Recent clinical study demonstrating the initial outcomes of the Pipeline Flex embolization device in the treatment of intracranial aneurysms.**
60. Martinez-Galdamez M, Gil A, Caniego JL, et al. Preliminary experience with the Pipeline Flex embolization device: technical note. J Neurointerv Surg. 2015;7(10):748–751.
• **Recent clinical study in Europe demonstrating the initial outcomes of the Pipeline Flex embolization device in the treatment of intracranial aneurysms.**
61. Makoyeva A, Bing F, Darsaut TE, et al. The varying porosity of braided self-expanding stents and flow diverters: an experimental study. AJNR Am J Neuroradiol. 2013;34(3):596–602.
62. Srinivas NR. Genetic CYP2C19 polymorphism dependent non-responders to clopidogrel therapy – does structural design, dosing and induction strategies have a role to play? Eur J Drug Metab Pharmacokinet. 2009;34(3–4):147–150.
63. Cuisset T, Quilici J, Cohen W, et al. Usefulness of high clopidogrel maintenance dose according to CYP2C19 genotypes in clopidogrel low responders undergoing coronary stenting for non ST elevation acute coronary syndrome. Am J Cardiol. 2011;108(6):760–765.
64. Delgado Almandoz JE, Crandall BM, Scholz JM, et al. Last-recorded P2Y12 reaction units value is strongly associated with thromboembolic and hemorrhagic complications occurring up to 6 months after treatment in patients with cerebral aneurysms treated with the Pipeline embolization device. AJNR Am J Neuroradiol. 2014;35(1):128–135.
65. Nordeen JD, Patel AV, Darracott RM, et al. Clopidogrel resistance by P2Y12 platelet function testing in patients undergoing neuroendovascular procedures: incidence of ischemic and hemorrhagic complications. J Vasc Interv Neurol. 2013;6(1):26–34.
66. Hanel RA, Taussky P, Dixon T, et al. Safety and efficacy of ticagrelor for neuroendovascular procedures. A single center initial experience. J Neurointerv Surg. 2014;6(4):320–322.
67. Martinez-Galdamez M, Ortega-Quintanilla J, Hermosin A, et al. Novel balloon application for rescue and realignment of a proximal end migrated Pipeline flex embolization device into the aneurysmal sac: complication management. J Neurointerv Surg. 2016 Mar 30. pii: neurintsurg-2016-012263.rep. doi:10.1136/neurintsurg-2016-012263.rep. [Epub ahead of print].
68. Briganti F, Leone G, Napoli M, et al. Early fatal hemorrhage after endovascular treatment of a giant aneurysm with flow diverter device and coils. Clin Neuroradiol. 2015;25(2):201–205.
69. Cebral JR, Mut F, Raschi M, et al. Aneurysm rupture following treatment with flow-diverting stents: computational hemodynamics analysis of treatment. AJNR Am J Neuroradiol. 2011;32(1):27–33.
70. Kulcsar Z, Houdart E, Bonafe A, et al. Intra-aneurysmal thrombosis as a possible cause of delayed aneurysm rupture after flow-diversion treatment. AJNR Am J Neuroradiol. 2011;32(1):20–25.
71. Siddiqui AH, Kan P, Abla AA, et al. Complications after treatment with Pipeline embolization for giant distal intracranial aneurysms with or without coil embolization. Neurosurgery. 2012;71(2):E509–E513;discussion E513.
•• **Recent clinical study demonstrating the difficulties, complications, and adjunctive therapies when treating giant aneurysms with flow diverters.**
72. Rouchaud A, Brinjikji W, Lanzino G, et al. Delayed hemorrhagic complications after flow diversion for intracranial aneurysms: a literature overview. Neuroradiology. 2016;58(2):171–177.
•• **Recent systematic review of delayed hemorrhagic complications in aneurysms treated with flow diverters.**
73. Brinjikji W, Murad MH, Lanzino G, et al. Endovascular treatment of intracranial aneurysms with flow diverters: a meta-analysis. Stroke. 2013;44(2):442–447.
• **Excellent meta-analysis of the literature on flow diverters in the treatment of intracranial aneurysms.**
74. Arrese I, Sarabia R, Pintado R, et al. Flow-diverter devices for intracranial aneurysms: systematic review and meta-analysis. Neurosurgery. 2013;73(2):193–199;discussion 199–200.
• **Excellent meta-analysis of the literature on flow diverters in the treatment of intracranial aneurysms.**
75. Szikora I, Berentei Z, Kulcsar Z, et al. Treatment of intracranial aneurysms by functional reconstruction of the parent artery: the Budapest experience with the Pipeline embolization device. AJNR Am J Neuroradiol. 2010;31(6):1139–1147.
•• **First case series in Europe with the Pipeline embolization device in the treatment of intracranial aneurysms.**
76. Chiu AH, Cheung AK, Wenderoth JD, et al. Long-term follow-up results following elective treatment of unruptured intracranial aneurysms with the Pipeline embolization device. AJNR Am J Neuroradiol. 2015;36(9):1728–1734.
77. Brinjikji W, Lanzino G, Cloft HJ, et al. Risk factors for ischemic complications following Pipeline embolization device treatment of intracranial aneurysms: results from the Intreped study. AJNR Am J Neuroradiol. 2016 Sep;37(9):1673–1678. doi:10.3174/ajnr.A4807. Epub 2016 Apr 21.
•• **Excellent subanalysis of the IntrePED registry in risk factors for ischemic complications after treatment of intracranial aneurysms with the Pipeline embolization device.**
78. Brinjikji W, Kallmes DF, Cloft HJ, et al.Age-related outcomes following intracranial aneurysm treatment with the Pipeline embolization device: a subgroup analysis of the intrePED registry. J Neurosurg. 2016 Jun;124(6):1726–1730. doi:10.3171/2015.5.JNS15327. Epub 2015 Nov 6.
•• **Excellent subanalysis of the IntrePED registry in age-related outcomes after treatment of intracranial aneurysms with the Pipeline embolization device.**
79. Lubicz B, Collignon L, Raphaeli G, et al. Flow-diverter stent for the endovascular treatment of intracranial aneurysms: a prospective study in 29 patients with 34 aneurysms. Stroke. 2010;41(10):2247–2253.
80. Park MS, Kilburg C, Taussky P, et al. Pipeline embolization device with or without adjunctive coil embolization: analysis of complications from the Intreped registry. AJNR Am J Neuroradiol. 2016 Jun;37(6):1127–1131. doi:10.3174/ajnr.A4678. Epub 2016 Jan 14.
•• **Excellent subanalysis of the IntrePED registry in adjunctive coil embolization in the treatment of intracranial aneurysms with the Pipeline embolization device.**
81. Kallmes DF, Brinjikji W, Boccardi E, et al. Aneurysm study of Pipeline in an observational registry (ASPIRe). Interv Neurol. 2016;5(1–2):89–99.
82. Martinez-Galdamez M, Perez S, Vega A, et al. Endovascular treatment of intracranial aneurysms using the Pipeline Flex embolization device: a case series of 30 consecutive patients. J Neurointerv Surg. 2016 Apr;8(4):396–401. doi:10.1136/neurintsurg-2015-011669. Epub 2015 Mar 13.
• **Recent clinical study demonstrating initial results in a multicenter study in Europe in the treatment of intracranial aneurysms with the Pipeline Flex embolization device.**
83. Le EJ, Miller T, Serulle Y, et al. Use of Pipeline Flex is associated with reduced fluoroscopy time, procedure time, and technical failure compared with the first-generation Pipeline embolization device. J Neurointerv Surg. 2016 Mar 9. pii: neurintsurg-2016-012261. doi:10.1136/neurintsurg-2016-012261. [Epub ahead of print].
• **Recent clinical study comparing the Pipeline Classic embolization devices and the Pipeline Flex embolization device in the treatment of intracranial aneurysms.**
84. El-Chalouhi N, Jabbour PM, Tjoumakaris SI, et al. Treatment of large and giant intracranial aneurysms: cost comparison of flow diversion and traditional embolization strategies. World Neurosurg. 2014;82(5):696–701.
85. Schuette AJ, Barrow DL. Flow diversion and the almighty dollar. World Neurosurg. 2014;82(5):583–585.
86. Shankar JJ, Vandorpe R, Pickett G, et al. SILK flow diverter for treatment of intracranial aneurysms: initial experience and cost analysis. J Neurointerv Surg. 2013;5(Suppl 3):iii11–15.

87. Withers K, Carolan-Rees G, Dale M. Pipeline embolization device for the treatment of complex intracranial aneurysms: a NICE Medical Technology Guidance. Appl Health Econ Health Policy. 2013;11 (1):5–13.
88. Shapiro M, Becske T, Nelson PK. Learning from failure: persistence of aneurysms following Pipeline embolization. J Neurosurg. 2016 May 6:1–8. doi:10.3171/2015.12.JNS152065. [Epub ahead of print].
• **Excellent analysis of single-center experience in persistent aneurysms after treatment with the Pipeline embolization device.**
89. Albuquerque FC, Park MS, Abla AA, et al. A reappraisal of the Pipeline embolization device for the treatment of posterior circulation aneurysms. J Neurointerv Surg. 2015;7(9):641–645.
90. Munich SA, Tan LA, Keigher KM, et al. The Pipeline embolization device for the treatment of posterior circulation fusiform aneurysms: lessons learned at a single institution. J Neurosurg. 2014;121 (5):1077–1084.
91. Chalouhi N, Zanaty M, Whiting A, et al. Treatment of ruptured intracranial aneurysms with the Pipeline embolization device. Neurosurgery. 2015;76(2):165-172;discussion 172.
92. Lin N, Brouillard AM, Keigher KM, et al. Utilization of Pipeline embolization device for treatment of ruptured intracranial aneurysms: US multicenter experience. J Neurointerv Surg. 2015;7(11):808–815.
93. Chalouhi N, Starke RM, Yang S, et al. Extending the indications of flow diversion to small, unruptured, saccular aneurysms of the anterior circulation. Stroke. 2014;45(1):54–58.
94. Girdhar G, Li J, Kostousov L, et al. In-vitro thrombogenicity assessment of flow diversion and aneurysm bridging devices. J Thromb Thrombolysis. 2015;40(4):437–443.
95. Murthy SB, Shah S, Shastri A, et al. The SILK flow diverter in the treatment of intracranial aneurysms. J Clin Neurosci. 2014;21(2):203–206.
96. Colby GP, Lin LM, Caplan JM, et al. Flow diversion of large internal carotid artery aneurysms with the surpass device: impressions and technical nuance from the initial North American experience. J Neurointerv Surg. 2016 Mar;8(3):279–286. doi:10.1136/neurintsurg-2015-011769. Epub 2015 May 18.
97. Wakhloo AK, Lylyk P, de Vries J, et al. Surpass flow diverter in the treatment of intracranial aneurysms: a prospective multicenter study. AJNR Am J Neuroradiol. 2015;36(1):98–107.
98. De Vries J, Boogaarts J, Van Norden A, et al. New generation of flow diverter (surpass) for unruptured intracranial aneurysms: a prospective single-center study in 37 patients. Stroke. 2013;44(6):1567–1577.
99. Kan P, Mokin M, Puri AS, et al. Successful treatment of a giant pediatric fusiform basilar trunk aneurysm with Surpass flow diverter. J Neurointerv Surg. 2016;8(6):e23.
100. Tan LA, Sandler V, Todorova-Koteva K, et al. Recovery of pituitary function following treatment of an unruptured giant cavernous carotid aneurysm using Surpass flow-diverting stents. J Neurointerv Surg. 2015;7(6):e20.
101. Möhlenbruch MA, Herweh C, Jestaedt L, et al. The FRED flow-diverter stent for intracranial aneurysms: clinical study to assess safety and efficacy. AJNR Am J Neuroradiol. 2015;36 (6):1155–1161.
102. Poncyljusz W, Sagan L, Safranow K, et al. Initial experience with implantation of novel dual layer flow-diverter device FRED. Wideochir Inne Tech Maloinwazyjne. 2013;8(3):258–264.
103. Diaz O, Gist TL, Manjarez G, et al. Treatment of 14 intracranial aneurysms with the FRED system. J Neurointerv Surg. 2014;6 (8):614–617.
104. Kocer N, Islak C, Kizilkilic O, et al. Flow re-direction endoluminal device in treatment of cerebral aneurysms: initial experience with short-term follow-up results. J Neurosurg. 2014;120(5):1158–1171.
105. Briganti F, Leone G, Ugga L, et al. Safety and efficacy of flow re-direction endoluminal device (FRED) in the treatment of cerebral aneurysms: a single center experience. Acta Neurochir (Wien). 2016;158(9):1745–1755.
106. Briganti F, Leone G, Marseglia M, et al. p64 flow modulation device in the treatment of intracranial aneurysms: initial experience and technical aspects. J Neurointerv Surg. 2016;8(2):173–180.
107. Briganti F, Leone G, Ugga L, et al. Mid-term and long-term follow-up of intracranial aneurysms treated by the p64 flow modulation device: a multicenter experience. J Neurointerv Surg. 2016 Jul 20. pii: neurintsurg-2016-012502. doi:10.1136/neurintsurg-2016-012502. [Epub ahead of print].
108. Fischer S, Aguilar-Pérez M, Henkes E, et al. Initial experience with p64: a novel mechanically detachable flow diverter for the treatment of intracranial saccular sidewall aneurysms. AJNR Am J Neuroradiol. 2015;36(11):2082–2089.
109. Ley D, Muhl-Benninghaus R, Yilmaz U, et al. The Derivo embolization device, a second-generation flow diverter for the treatment of intracranial aneurysms, evaluated in an elastase-induced aneurysm model. Clin Neuroradiol. 2015 Dec 23. doi:10.1007/s00062-015-0493-9. [Epub ahead of print].