Surgical Neurology International

OPEN ACCESS

For entire Editorial Board visit : http://www.surgicalneurologyint.com

Editor: James I. Ausman, MD, PhD University of California, Los Angeles, CA, USA

Case Report

Giant clival chordoma causing pathological laughter

Daniel Andrade Gripp, Antonio Aversa do Souto, Douglas Gonsales, Marcio de Miranda Chaves Christiani, Janio Nogueira, Helio Ferreira Lopes, Yasmine Coura Torres

Department of Neurosurgery, National Institute of Cancer, INCA, Centro, Rio de Janeiro, Brazil

E-mail: *Daniel Andrade Gripp - danielgripp@uai.com.br; Antonio Aversa do Souto - aversadosouto@gmail.com; Douglas Gonsales - douglasgonsales@brturbo.com.br; Marcio de Miranda Chaves Christiani - marciomcc@yahoo.com; Janio Nogueira - JanioNogueira@inca.gov.br; Helio Ferreira Lopes - Hlopes@inca.gov.br; Yasmine Coura Torres - yasminectorres@gmail.com
*Corresponding author

Received: 06 May 13 Accepted: 15 January 14 Published: 17 February 14

This article may be cited as:
Gripp DA, do Souto AA, Gonsales D, Christiani MC, Nogueira J, Lopes HF, *et al*. Giant clival chordoma causing pathological laughter. Surg Neurol Int 2014;5:18.
Available FREE in open access from: http://www.surgicalneurologyint.com/text.asp?2014/5/1/18/127257

Abstract

Background: Chordomas are rare slowly growing tumors that originate from remnants of the notochord. They have a malignant local behavior, causing symptoms due to bone infiltration and compression of neurovascular structures. Only a few cases of brain tumors associated with pathological laughter have been reported in the literature.

Case Description: We report a case of a 42-year-old male patient with this atypical clinical presentation treated at our institution, and discuss the concerning literature.

Conclusion: Although being a very rare presentation of chordomas, pathological laughter is usually expected to improve after brain stem decompression.

Key Words: Chordoma, clivus, pathological laughter

Access this article online
Website: www.surgicalneurologyint.com
DOI: 10.4103/2152-7806.127257
Quick Response Code:

INTRODUCTION

The authors describe a case of a giant clivus chordoma in a 42-year-old male presenting with symptoms due to compression of the brain stem and hypothalamus, including the unusual manifestation of pathological laughter. He was treated by an endoscopic transphenoidal approach. This was an unusual case of a neoplastic condition associated with pathological laughter treated at our institution. We review and discuss the pathophysiology and most common causes of this rare condition, which might be associated with tumors occurring in the posterior fossa region, as already reported by other authors.

CASE REPORT

A 42 year-old male patient was admitted with a history of headache, which started approximately one year ago. He had been followed in another institution as a pituitary adenoma and had not had surgery before coming to our consultation. In the past 3 months he complained of worsening of the headache, diplopia, and diminished bilateral visual acuity. He had at this time many episodes of unmotivated laugh without consciousness disruption. They were self-limited lasting for a few seconds only. At examination, an intense ataxia, global hyperreflexia, bitemporal hemianopia, and mild right VI nerve paresis were remarkable. Panhypopituitarism was evident in laboratory exams. Eletroencephalogram did not reveal seizure activity. Neuroimaging revealed a large clival mass invading the sphenoid sinus with destruction of the sella with a huge suprasellar and retrosellar extension, brain stem displacement and skull base bone destruction [Figures 1 and 2]. We performed a binostril, transnasal transphenoidal endoscopic approach with bilateral medial turbinectomy, wide opening of the

anterior wall of the sphenoid sinus, and a radical resection of the lesion with partial resection of the infiltrated clival dura. Satisfactory brain stem decompression was accomplished [Figures 3 and 4]. Reconstruction of the skull base was achieved with abdominal fat, nasoseptal pediculated graft (Haddad) and fibrin glue. Postoperative period was uneventful with no cerebrospinal fluid leakage episodes and a great improvement in vision, with total recovering of the VI nerve deficit and ataxia. He has not had any paroxysm of pathological laughter since surgery. Histological examination confirmed the diagnosis of chordoma. Patient was submitted in the postoperative period to radiotherapy (IMRT) and has been asymptomatic in the past 14 months. Follow up magnetic resonance imaging (MRI) is shown in [Figures 5 and 6].

DISCUSSION

Chordomas are rare, slowly growing neoplasms that presumably originate from remnants of the notochord. After birth, the only remaining normal notochordal elements are the nuclei pulposi; however, notochordal remnants may remain along the neural axis, and these ectopias may be the substrates from which chordomas arise.[1] These tumors are usually more common in adults, with a peak incidence in the fourth decade. Fewer than 5% of these tumors are diagnosed in patients 20 years of age or younger.[1] They arise most commonly in the sacrococcygeal region. The second most common place is sphenoccipital region. Metastases are rare but there is a high recurrence rate even after radical resection, this being usually the initial treatment. High dose radiotherapy, IMRT or stereotactic radio-surgery may be used as an adjunctive treatment. Proton beam therapy, although not available in our country, is known to be more effective than conventional radiotherapy alone.

Pathological laughter is a very rare symptom associated with brain tumors. Its physiopathology is still not well understood. By definition it is an unmotivated laughing or laughing triggered by inappropriate stimulus that otherwise would not have caused the individual to laugh.[8]

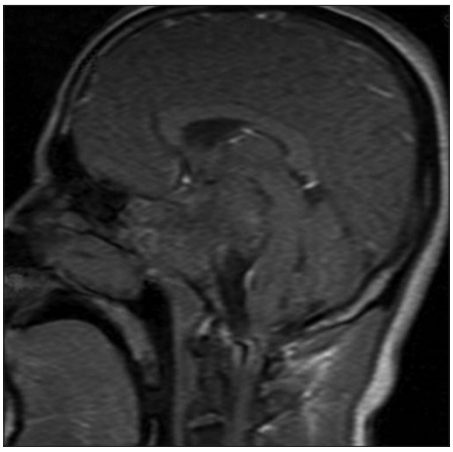

Figure 1: T1 MRI imaging showing clival lesion, osseous destruction and brain stem displacement

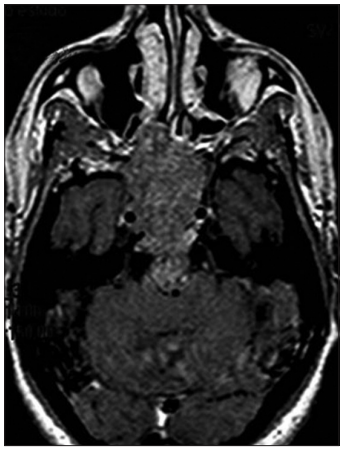

Figure 2: T1 postcontrast MRI imaging showing sphenoid sinus invasion

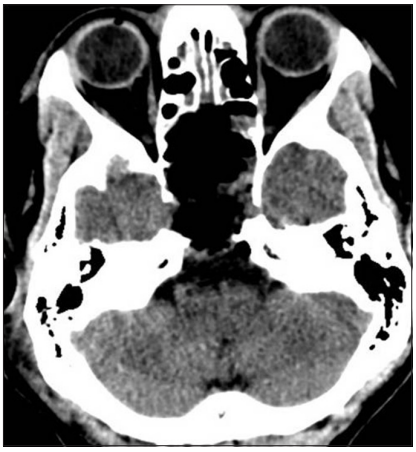

Figure 3: Postoperative scan showing radical tumor resection

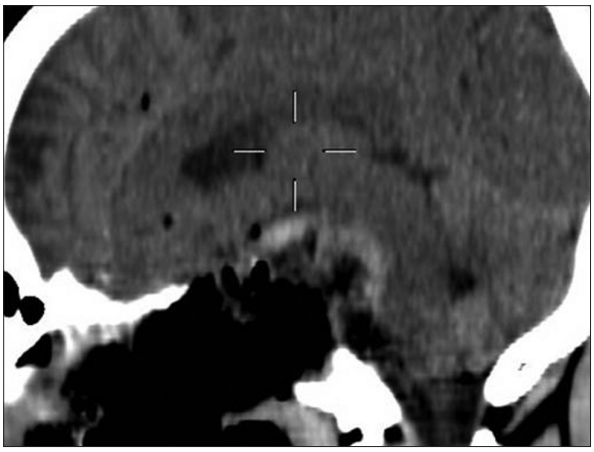

Figure 4: Sagittal postoperative scan showing brain stem decompression

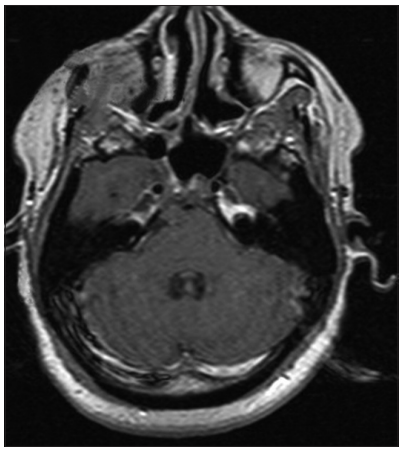

Figure 5: Axial postoperative MRI T1 imaging showing no signs of recurrent tumor

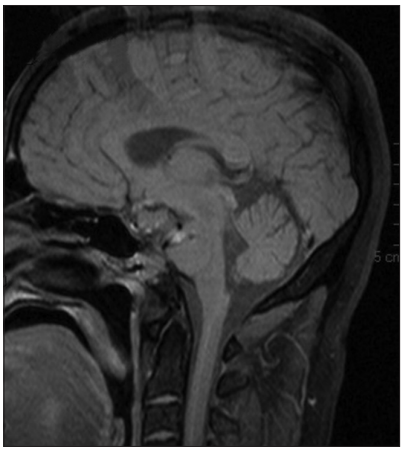

Figure 6: Sagittal MRI T1 imaging showing residual fat and no signs of tumor recurrence

There is no cortical isolated area for the control of emotional responses such as laughing. Many cortical and subcortical areas, as well as brain stem regions are probably involved with laughing. The amygdala, thalamic/hypothalamic and subthalamic areas and the dorsal tegmental brain stem seem to be part of what is called an involuntary pathway. In contrast, a presumed voluntary pathway originates in the premotor/frontal opercular areas and extends through the motor cortex and pyramidal tract to the ventral brain stem. These pathways and the laughter response appear to be coordinated by a laughter-coordinating center in the dorsal upper pons.[8]

Abnormal pontine BOLD (blood oxygen level dependent) signal on functional MRI has been reported by Kosaka[6] in one patient presenting pathological laughter, and no control subjects demonstrated the same response, during repetitive semantic tasks, supporting that hypothesis.

Cerebellum and its connections have also been implicated to play a role in patients experiencing pathological laughter. They appear to modulate responses to external stimulus allowing the emotional expressions to be scaled down or even inhibited when socially appropriate. Lesions affecting the cerebellum itself or its projections might disrupt those mechanisms, as reported by Parvizi.[8]

Either diffuse or focal lesions interrupting these pathways may be responsible for this phenomenon. Chronic disinhibition of the laughter generating circuitry seems to be the neurophysiological anatomical basis.[9]

Reports of organic causes of pathological laughter include trauma, demyelinating disorders, vascular diseases, and intracranial tumors.

Pathological laughter is the main manifestation of gelastic seizures, which are a rare epileptic syndrome most commonly found in patients harboring hypothalamic hamartomas.[3]

Stroke has been associated with unmotivated laughter, the phenomenon being known as fou rire prodromique. Garg reported a patient with pathological laughter preceding a cortical infarct in the territory supplied by superior division of middle cerebral artery.[4] Unmotivated laughter has also been associated with vascular lesions of the pons, parahyppocampal gyrus and thalamus.

Pathological laughter has also been reported in patients harboring intracranial lesions, although not too many cases in the literature have been reported so far.

Matsuoka described the case of a 40-year-old male with a clival chordoma who presented with symptoms of pathological laughter and left sixth cranial nerve paresis.[5]

Bhatjiwale reported four cases of trigeminal neuromas that presented with this same symptom.[2] Trigeminal neuroma was also the cause of the unmotivated laughing of the patient reported by Machado.[7]

Borba, reviewing cases of chordomas in patients aged younger than 20 years, had one case of tumor manifesting with pathological laughter.[1]

Brain stem displacement was common to all those cases described, also being observed in our patient. We relate this unusual symptom to this finding. In posterior fossa tumors associated with pathological laughter, the condition is usually expected to improve after brain stem decompression, as was observed in our patient.

CONCLUSION

Pathological laughter is a rare symptom that can be present in some neurological conditions including posterior fossa tumors. It is believed to be related to brain stem compression and disruption of its intrinsic pathways and connections to supra tentorial regions, as stated in other reports. Complete relief of the condition can be

expected after surgical treatment and decompression of the brain stem.

REFERENCES

1. Borba LA, Al-Mefty O, Mark RE, Suen J. Cranial chordomas in children and adolescents. J Neurosurg 1996;84:584-91.
2. Bhatjiwale MG, Nadkarni TD, Desai KI, Goal A. Pathological laughter as a presenting symptom of massive trigeminal neuromas: Report of four cases. Neurosurgery 2000;47:469-72.
3. Cascino GD, Andermann F, Berkovic SF, Kuzniecky RI, Sharbrough FW, Keene DL, *et al*. Gelastic seizures and hypothalamic hamartomas.Evaluation of patients undergoing chronic intracranial EEG monitoring and outcome of surgical treatment. Neurology 1993;43:747-50.
4. Garg RK, Misra S, Verma R. Pathological laughter as heralding manifestation of left middle cerebral artery territory infarct: Case report and review of literature. Neurol India 2000;48:388-90.
5. Matsuoka S, Yokota A, Yasukouchi H, Harada A, Kadoya C, Wada S, *et al*. Clival chordoma associated with pathological laughter. Case report. J Neurosurg 1993;79:428-33.
6. Kosaka H, Omata N, Omori M, Shimoyama T, Murata T, Kashikura K, *et al*. Abnormal pontine activation in pathological laughing as shown by functional magnetic resonance imaging. J Neurol Neurosurg Psychiatry 2006;77:1376-80.
7. Machado AG, Aguiar PH, Marino R Jr. Pathological laughter in a patient with trigeminal neurinoma. Arq Neuropsiquiatr 2000;60:1000-2.
8. Parvizi J, Anderson SW, Martin CO, Damasio H, Damasio AR. Pathological laughter and crying: A link to the cerebellum. Brain 2001;124:1708-19.
9. Wild B, Rodden FA, Grodd W, Ruch W. Neural correlates of laughter and humor. Brain 2003;126:2121-38.